

# Socket preservation with demineralized freeze-dried bone allograft and platelet-rich fibrin for implant site development: A randomized controlled trial

Ridhima Dhamija<sup>1</sup>, Vibha Shetty<sup>1</sup>, K. Vineeth<sup>2</sup>, Rakesh Nagaraju<sup>3</sup>, Roopa S. Rao<sup>4</sup>

Departments of <sup>1</sup>Prosthodontics, <sup>2</sup>Oral and Maxillofacial Surgery, <sup>3</sup>Oral Medicine and Radiology and <sup>4</sup>Oral and Maxillofacial Pathology, M S Ramaiah Dental College and Hospital, Bengaluru, Karnataka, India

## Abstract

**Aim:** This *in vivo* study compared clinical, histological, and radiological differences in bone formation in human extraction sockets grafted with demineralized freeze-dried bone allograft (DFDBA) and platelet-rich fibrin (PRF), with nongrafted sockets and bone-implant contact (BIC) at 3 and 6 months after implant placement.

**Settings and Design:** Randomised controlled trial.

**Materials and Methods:** The study comprised thirty posterior teeth sockets in either arch in patients ranging from 25 to 60 years. The patients were divided into two equal groups – Group I: control group wherein no graft was placed and the extraction socket was left to heal normally and Group II: test group in which DFDBA and PRF were placed after extraction. 12–16 weeks after extraction, a trephine biopsy was done just prior to implant placement, followed by implant placement. Cone-beam computed tomography (CBCT) at 3 and 6 months after implant placement was done to assess BIC.

**Statistical Analysis Used:** Descriptive and Inferential statistical analysis was done. Parametric test: Independent t-test was used for intergroup analysis and dependent t-test for intra-group analysis.

**Results:** Lower buccal bone levels were seen in the control group versus test group at all intervals though moderately significant. Lingual bone levels significantly reduced at all the three intervals for the control group as compared to the test group. Ridge width in both groups reduced in a time span of 6–7 months without any significant difference. Better bone conversion was noted in the preserved sockets. The preserved sockets also showed better BIC 3 months after implant placement and loading.

**Conclusion:** Indigenously developed DFDBA material shows promising results as an osteoinductive material.

**Keywords:** Socket preservation, bone-implant contact, ridge height, demineralized freeze-dried bone allograft, platelet-rich fibrin

**Address for correspondence:** Dr. Ridhima Dhamija, Ground Floor, E-3/4, Dlf Phase-1, Gurugram - 122 002, Haryana, India.

E-mail: [ridhima.1810@gmail.com](mailto:ridhima.1810@gmail.com)

**Submitted:** 05-Jan-2020, **Revised:** 27-May-2020, **Accepted:** 22-Jun-2020, **Published:** 17-Jul-2020

## INTRODUCTION

Edentulism is a debilitating condition leading to both ridge height and width loss.<sup>[1]</sup> Implant-supported fixed prosthesis

ensures improved esthetic and functional restoration of missing teeth in terms of keratinized mucosa width, gingival

Access this article online	
Quick Response Code: 	Website: <a href="http://www.j-ips.org">www.j-ips.org</a>
	DOI: <a href="https://doi.org/10.4103/jips.jips_2_20">10.4103/jips.jips_2_20</a>

This is an open access journal, and articles are distributed under the terms of the Creative Commons Attribution-NonCommercial-ShareAlike 4.0 License, which allows others to remix, tweak, and build upon the work non-commercially, as long as appropriate credit is given and the new creations are licensed under the identical terms.

**For reprints contact:** [reprints@medknow.com](mailto:reprints@medknow.com)

**How to cite this article:** Dhamija R, Shetty V, Vineeth K, Nagaraju R, Rao RS. Socket preservation with demineralized freeze-dried bone allograft and platelet-rich fibrin for implant site development: A randomized controlled trial. *J Indian Prosthodont Soc* 2020;20:304-11.

recession, and papilla fill, improving chewing efficiency and enhancing psychological benefit for the patient.<sup>[2,3]</sup> Thus, placement of dental implants and ridge preservation through graft materials can successfully rehabilitate an edentulous site.<sup>[4-6]</sup>

The present study was undertaken with the objectives of evaluating and comparing clinical and histological differences in bone formation in human sockets grafted with a mixture of demineralized freeze-dried bone allograft (DFDBA) and platelet-rich fibrin (PRF), with nongrafted sockets, and determining the bone–implant contact (BIC) ratio with cone-beam computed tomography (CBCT), at 3 months after implant placement and 3 months after loading.

## MATERIALS AND METHODS

### Source of data

This study enrolled patients aged 25–60 years of both genders reporting to the Department of Prosthodontics, Department of Oral and Maxillofacial Surgery, and Department of Implantology, M S Ramaiah Dental College and Hospital, Bengaluru, for extraction and replacement of missing teeth with dental implants. The timeframe of the study ranged from December 2014 to September 2016.

### Sample size and study design

In a study involving a histologic analysis, it was observed that about  $65 \pm 10\%$  of patients who received ridge preservation using freeze-dried bone allograft and a collagen membrane developed more bone versus  $54 \pm 12\%$  in the patients who received extraction alone.<sup>[7]</sup> Extrapolating these results to the present study, to obtain 80% power and 95% confidence level, a sample size of 30 was chosen.

- Group I: Control group – no graft was placed, and extraction socket was left to heal normally
- Group II: Test group, i.e., the socket was preserved with DFDBA, and PRF was placed after extraction.

The study design was a randomized controlled clinical trial [Figure 1]. The inclusion, exclusion, and exit criteria were as follows.

### Inclusion criteria

- Patients without any systemic disease with tooth indicated for extraction eg: fractured tooth, nonvital tooth without the possibility of endodontic treatment, endodontic treatment failure.
- Patients' choice of replacement with implant-supported fixed prosthesis
- Extraction socket with four intact walls immediately after the extraction of tooth.

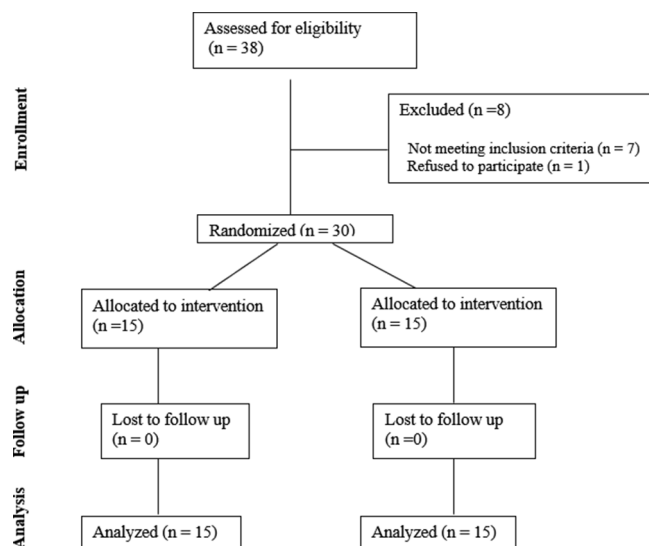


Figure 1: CONSORT flow diagram – flow diagram for randomization

### Exclusion criteria

- Surgical complications during extraction including loss of buccal or lingual/palatal cortical plate
- Development of oral or systemic disease
- Presence of any chronic systemic disease such as osteoporosis and diabetes mellitus
- Heavy smokers (over ten cigarettes/day)
- Chronic treatment with any medication known to affect bone turnover such as heparin, cyclosporine, bisphosphonates, and chemotherapeutic drugs – methotrexate.

### Exit criteria

Voluntary withdrawal and development of oral or systemic disease.

The objectives of the study were to assess the following:

1. Clinical ridge height and width after extraction with and without socket preservation
2. Bone formation after extraction with and without socket preservation by means of histological analysis
3. Bone–implant contact at 3 months after implant placement and 3 months after implant loading in nongrafted and grafted sockets.

### Patients

In this prospective clinical study, patients with thirty sites reported to the Department of Prosthodontics for replacement of missing posterior teeth (maxillary/mandibular). All the patients were evaluated as per standard norms and were selected according to the inclusion and exclusion criteria. The participants had the ability to understand the proposed treatment and its prognosis and provide informed consent, in English,

without the aid of *ad hoc* translation. These patients were randomly allotted to two groups using concealed envelope allotment method where they were blinded to the outcome of the envelope picked. The study was presented to the Ethical Committee of M S Ramaiah Dental College and Hospital Ethical committee number- MSRDC/ EC/2014-15/05).

### Presurgical procedure

All the patients were subjected to routine blood investigations – hemoglobin%, Bleeding Time/Clotting Time, and glycated hemoglobin. A prophylactic regimen included amoxicillin (2 g) 1 h preoperatively and 500 mg three times daily for 5 days postoperatively. None of the patients reported or demonstrated any allergy to amoxicillin. Prior to extraction, impressions and diagnostic casts were made. On the study cast, modeling wax of 0.5 cm × 0.5 cm was added in two layers on the crown of the tooth indicated for extraction to stabilize a small piece of wire on it to define a standard reference point. An auto-polymerizing resin material was used to fabricate the template/stent on this study model including at least one tooth anterior or posterior to the indicated tooth. From this metal wire, ridge height measurements were made clinically, till the cervical level of the tooth (0 mm). Two more measurements were marked cervical to the first marking, at 2 mm and 6 mm distance, with the help of a Williams probe. After the height measurements were accomplished, the width was measured at 2 mm and 6 mm levels with a bone gauge.

### Platelet-rich fibrin preparation (for Group 2)-procedure

5 ml of whole venous blood was collected from each patient at the time of implant placement, in sterile vacutainer tubes of 6-ml capacity without anticoagulant. The vacutainer tubes were then placed in a centrifugal machine REMI R-4C (REMI Laboratory Instruments, Mumbai, India) at 3000 revolutions per minute (rpm) for 10 min at room temperature after which it settled into the following layers: red lower fraction containing red blood cells, upper straw-colored cellular plasma, and the middle fraction containing the fibrin clot. The upper straw-colored layer was removed, and the middle fraction which is the PRF was collected up to 2 mm below the lower dividing line.<sup>[8]</sup>

### Surgical extraction procedure

All procedures were performed by a single experienced clinician. A preprocedural rinse was performed (0.12% chlorhexidine gluconate for 1 min), and the lower third of the face was scrubbed with povidone iodine. Local anesthetic (Lox 2% Adr, 1:200,000) was administered, and the tooth was extracted with minimal trauma using

periotomes. Flap elevation was done to ensure primary closure.<sup>[9]</sup> The use of extraction forceps was limited to minimum, to preserve the socket walls. The integrity of the remaining socket walls was assessed. The sockets were thoroughly debrided with a socket curette and irrigated well with saline. In Group 1, the sockets were closed with primary closure with minimal tension (with 3-0 nonresorbable silk sutures). In Group 2, the DFDBA graft material (DFDBA 500–1000 µ particulate, gamma irradiated, lyophilized graft material – 0.5 cc vial for each test group socket, obtained from Tata Memorial Hospital, Mumbai) mixed with PRF was packed into the socket (followed by suturing identical to that of the control group). The patients were recalled after a week for assessment and suture removal.

### Preimplant procedure

Following the delayed two-stage implant placement protocol, 12–16 weeks later, socket fill was assessed with an intraoral periapical radiograph. At the same time, ridge height and width measurements were calculated again, using the stent, as done before the implant placement was begun.

### Trephine biopsy for histological assessment

All surgical placements of implants were done by a single experienced operator. After administration of local anesthetic, full-thickness mucoperiosteal flaps were raised and initial pilot drill was replaced by a trephine of same diameter to remove the core from the required site. A 2 mm × 6 mm trephine-latch type, with an internal diameter of 2 mm, attached to a contra-angle micro-motor hand piece was positioned at the center of every socket with the use of a surgical guide, with copious chilled saline irrigation followed by a periapical radiograph to ensure correct orientation. The trephine core was gently teased out of the drill directly into 10% neutral buffered formalin, and the containers were appropriately labeled. The samples were processed for histologic evaluation.

### Implant placement procedure

After the trephine biopsy, the osteotomy site was prepared with sequential drilling to receive Hi-Tech implant of appropriate dimensions, as determined from the preoperative CBCT. Following placement of implant and cover screw, flaps were closed achieving primary closure. Antibiotics and appropriate analgesics were prescribed. Postoperative instructions were given. Postoperative healing was uneventful. After a week, the sutures were removed.

### Histological and histomorphological analysis

This is a gold standard to determine bone cells and its

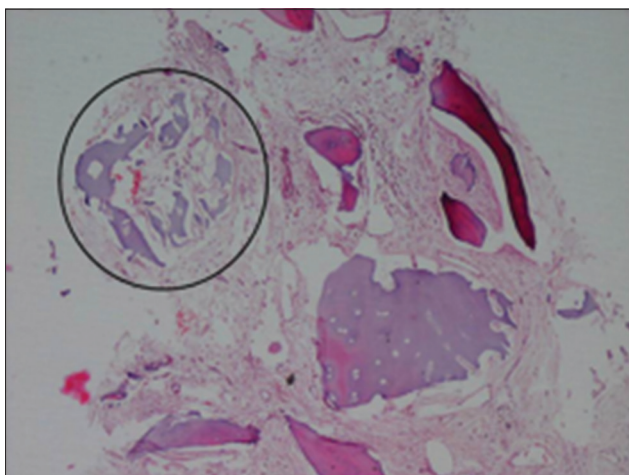
activities.<sup>[10]</sup> The specimens were labeled and submitted for histopathological evaluation. To avoid bias, the entire procedure was blinded and reported by more than one pathologist. The trephine core biopsies were first decalcified using 5% nitric acid solution. Ascertaining the cores were soft, they were taken for tissue processing. Post processing, the cores were embedded longitudinally in paraffin blocks. Subsequently, sections of 4 μ were sectioned from the paraffin block using an automatic Leica tissue microtome and were stained with H and E stain. Thirty histologic sections were examined under the binocular Olympus microscope (Olympus Corp., Tokyo, Japan) and were photo-micrographed using the Jenopik ProgRes camera at ×4 magnification. Following which, the photomicrographs were uploaded to Motic image analyzer software version 2.0 (china group co. ltd, Shenzhen, China) to calculate the percentage of bone, trabecular space, and graft. The obtained percentages were tabulated, and statistical analysis was performed using paired *t*-test within the groups and using unpaired *t*-test between the groups.

Histologically, the grafts appeared as homogenous masses with irregular borders, devoid of osteocytes and no evidence of osteoblastic/osteoclastic activity [Figure 2].

### Radiological assessment

Three-dimensional (3D)-imaging techniques have the advantages of negligible magnification, relatively high contrast images, various views, and reduced dose of radiation to the patient as compared to other imaging modalities.<sup>[11]</sup> Therefore, CBCT was used to conduct this study.

All implants were clinically stable without mobility or any signs or symptoms of inflammation at the time of CBCT. A single experienced oral and maxillofacial radiologist



**Figure 2:** Photomicrograph of the graft material – grafts appeared as homogenous masses with irregular borders, devoid of osteocytes and no evidence of osteoblastic/osteoclastic activity

carried out radiographic assessments by reconstruction and measurement of the images. For each implant, CBCT images were made using Carestream 9300 premium CBCT scanner and CS 3D dental imaging software version 6.3 (Carestream dental LLC, Atlanta, Georgia, USA) with the exposure parameters of 90 kVp and 6.3 mA and voxel size of 180 μm with an exposure time of 8 s at an interval of 3 months and 6 months.

For each individual BIC measurement, the following parameters were considered at an interval of 3 months and 6 months:

1. Length of the implant covered by bone on buccal and lingual/palatal surface – Measured from the alveolar crest to the apex of the implant in the sagittal section
2. Length of the implant covered by the bone on the mesial and distal surfaces – Measured from the alveolar crest to the apex of the implant on the mesial and distal surfaces in the coronal section.

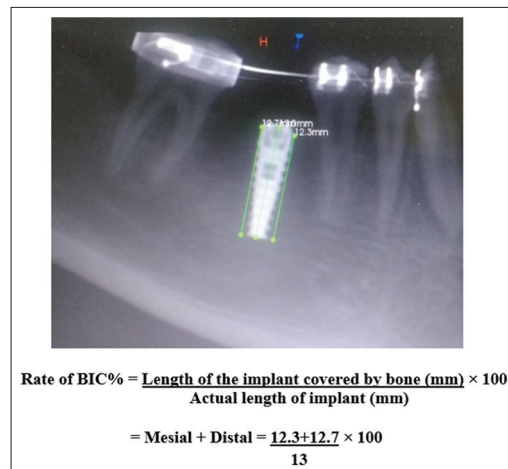
The BIC was assessed using the following formula<sup>[12]</sup> in buccal, lingual, mesial, and distal surfaces of the implant:

$$\text{Rate of BIC\%} = \frac{\text{Length of the implant covered by the bone}}{\text{Actual length of the implant}} \times 100$$

The average of the mesial and distal BIC measurements was taken, while the palatal and buccal BIC measurements were calculated individually [Figure 3].

### Statistical analysis

This was performed using two-tailed *t*-test (independent) to find the significance of study parameters on a continuous scale between two groups (intergroup analysis) on metric



**Figure 3:** Calculation of bone–implant contact on the mesial and distal sides

parameters. Two-tailed *t*-test (dependent) was used to find the significance of study parameters on a continuous scale within each group.

### Statistical methods

Descriptive and inferential statistical analysis was carried out in the present study. Results on continuous measurements were presented on mean  $\pm$  standard deviation (minimum–maximum), and results on categorical measurements were presented in number (%). Significance was assessed at 5% level of significance. The following assumptions on data were made.

1. Dependent variables were normally distributed
2. Samples drawn from the population were random. independent *t*-test (two tailed) was used to find the significance of the study parameters on continuous scale between two groups (intergroup analysis). Two tailed *t*-test (dependent) was used to find the significance of study parameters on a continuous scale within each group.

### Significant figures

\*Suggestive significance ( $P: 0.05 < P < 0.10$ ); \*moderately significant ( $P: 0.01 < P \leq 0.05$ ); and \*\*strongly significant ( $P: P \leq 0.01$ ).

### Statistical software

The statistical software namely SPSS version 15.0 (SPSS, Chicago, USA) was used for analysis of data, and Microsoft Word and Excel were used to generate graphs, tables, etc.

## RESULTS

1. The study comprised thirty sockets (having 15 control and 15 test sockets) from patients ranging from 25 to 60 years. The mean age in the test group was  $41.93 \pm 13.87$  years, whereas in the control group was  $48.47 \pm 13.26$  years. The study group consisted of nine (60%) males and six (40%) females, whereas the control group comprised nine (60%) males and six (40%) females. The samples were gender ( $P = 1.000$ ) and age matched ( $P = 0.198$ ) as shown in Tables 1 and 2
2. Clinical measurements
  - a. Ridge height – Table 3 shows the distance from the metal wire of the acrylic stent to the baseline = Ref 1 (at the crest = 0 mm), Ref 1 + 2 mm from the crest [=Ref 2], and Ref 1 + 6 mm from the crest [=Ref 3]. All these measurements were taken at the buccal and the lingual aspects of the tooth in question, at three intervals – before extraction; 12–16 weeks postextraction that is

**Table 1: Gender distribution of the patients studied**

Gender	Control (%)	Test (%)	Total (%)
Male	9 (60)	9 (60)	18 (60)
Female	6 (40)	6 (40)	12 (40)
Total	15 (100)	15 (100)	30 (100)

Samples are gender matched with  $P=1.000$

**Table 2: Age distribution of the patients studied**

Age (years)	Control (%)	Test (%)	Total (%)
21-30	2 (13.3)	5 (33.3)	7 (23.3)
31-40	2 (13.3)	3 (20)	5 (16.7)
41-50	2 (13.3)	0 (0)	2 (6.7)
>50	9 (60)	7 (46.7)	16 (53.3)
Total	15 (100)	15 (100)	30 (100)
Mean $\pm$ SD	48.47 $\pm$ 13.26	41.93 $\pm$ 13.87	45.20 $\pm$ 13.74

Samples are age matched with  $P=0.198$ . SD: Standard deviation

- a. Ridge height – Table 3 shows the distance from the metal wire of the acrylic stent to the baseline = Ref 1 (at the crest = 0 mm), Ref 1 + 2 mm from the crest [=Ref 2], and Ref 1 + 6 mm from the crest [=Ref 3]. All these measurements were taken at the buccal and the lingual aspects of the tooth in question, at three intervals – before implant placement; and 3 months post implant placement
- b. The Ref 1 distance on the lingual aspect increased with moderate significance ( $P = 0.025$ ) in the control group ( $8.07 \pm 2.46$ ) as compared to the test group ( $6.40 \pm 1.18$ ) before extraction [Table 3]
- c. The Ref 1 distance before implant placement on the buccal aspect increased with moderate significance ( $P = 0.023$ ) in the control group ( $9.40 \pm 2.13$ ) as compared to the test group ( $7.67 \pm 1.80$ ) and with moderate significance ( $P = 0.031$ ) in the control group ( $9.73 \pm 2.58$ ) as compared to the test group ( $8.0 \pm 1.46$ ) on the lingual aspect also, showing more ridge height loss on the buccal and lingual aspects in the control group [Table 3]
- d. Three months post implant placement, on the buccal aspect, Ref 1 distance increased with suggestive significance (0.059) in the control group ( $9.47 \pm 2.10$ ) as compared to the test group ( $8.07 \pm 1.79$ ) and on the lingual aspect also with suggestive significance (0.074) in the control ( $9.87 \pm 2.61$ ) as compared to the test group ( $8.40 \pm 1.59$ ), showing more ridge height loss on the buccal and lingual aspects in the control group [Table 3]
- e. Ridge width – Ridge width at Ref 2 showed no significant difference before extraction ( $P = 0.281$ ), before implant placement ( $P = 0.887$ ), and 3 months post implant placement ( $P = 1.000$ ) [Table 4]. In addition, ridge width at Ref 3 showed no statistically significant difference before extraction ( $P = 0.535$ ), before implant placement ( $P = 0.346$ ), and 3 months post implant placement ( $P = 0.366$ ) [Table 4]. In both groups, ridge width reduced in a time span of 6–7 months but did not show any significant difference between the groups [Table 4].

3. Histological evaluation – As shown in Table 5, the percentage of bone formed and trabecular space showed insignificant difference in both groups. Qualitative statistical analysis was done using paired Student's *t*-test within groups and unpaired Student's *t*-test between groups. The intraobserver reliability was shown to be good as the paired Student's *t*-test showed no significant difference.
4. Radiological evaluation – A quantitative analysis was carried out as described below.
  - a. Mesial + distal BIC percentage showed no significant difference between the control and the test groups at 3 months and postloading, that is, at 6 months. The intraobserver reliability was good [Table 6]
  - b. As shown in Table 7, buccal BIC percentage showed no significant difference between the control and the test groups at 3 months and at 6 months and within the groups at the same intervals. The intraobserver reliability was good
  - c. As shown in Table 8, palatal/lingual BIC percentage showed no significant difference between the control and the test groups at 3 months and at 6 months and within the groups at the same intervals. The intraobserver reliability was good.

## DISCUSSION

The cascading consequences of edentulism can be minimized with high-quality oral health care being given right from

**Table 3: Ridge height at crest (mm)**

Ridge height at crest (mm) <sup>[1]</sup>	Before extraction		Before implant placement		3 months after implant placement	
	Buccal	Lingual	Buccal	Lingual	Buccal	Lingual
Control	7.33±2.44	8.07±2.46	9.40±2.13	9.73±2.58	9.47±2.10	9.87±2.61
Test	6.07±1.67	6.40±1.18	7.67±1.80	8.00±1.46	8.07±1.79	8.40±1.59
Total	6.70±2.15	7.23±2.08	8.53±2.13	8.87±2.24	8.77±2.05	9.13±2.26
<i>P</i>	0.108	0.025*	0.023*	0.031*	0.059 <sup>+</sup>	0.074 <sup>+</sup>

**Table 4: Ridge width (mm)**

Ridge width	Before extraction		Before implant placement		3 months after implant placement	
	At 2 mm	At 6 mm	At 2 mm	At 6 mm	At 2 mm	At 6 mm
Control	11.13±2.03	13.20±2.43	8.53±1.41	11.13±2.00	8.13±1.41	10.60±1.92
Test	11.87±1.60	13.73±2.22	8.60±1.12	10.47±1.81	8.13±1.30	10.00±1.65
Total	11.50±1.83	13.47±2.30	8.57±1.25	10.80±1.90	8.13±1.33	10.30±1.78
<i>P</i>	0.281	0.535	0.887	0.346	1.000	0.366

**Table 5: Percentage of bone formed and trabecular space in the two groups**

Histological evaluation	Percentage of bone formed				Percentage of trabecular space			
	Measurement 1	Measurement 2	Difference ( <i>D</i> )	<i>P</i>	1	2	<i>D</i>	<i>P</i>
Control	53.05±15.43	52.70±15.53	0.346	0.231	46.95±15.43	47.30±15.53	-0.345	0.233
Test	57.32±19.94	57.13±20.41	0.187	0.418	41.18±19.59	41.35±20.02	-0.167	0.475
Total	55.18±17.65	54.92±17.96			44.07±17.57	44.32±17.86		
<i>P</i>	0.517	0.509			0.377	0.371		

**Table 6: Mesial plus distal bone-implant contact (%)**

M+D BIC (%)	Measurement 1		Measurement 2		Difference		<i>P</i>	
	3 months	6 months	3 months	6 months	3 months	6 months	3 months	6 months
Control	85.87±12.96	83.87±10.86	85.80±13.28	83.73±10.94	0.067	0.133	0.806	0.334
Test	87.73±11.35	88.07±9.87	87.87±11.06	87.87±9.96	-0.133	0.200	0.653	0.271
Total	86.80±12.00	85.97±10.42	86.83±12.06	85.80±10.49				
<i>P</i>	0.678	0.277	0.647	0.288				

BIC: Bone-implant contact

**Table 7: Buccal bone-implant contact (%)**

Buccal BIC (%)	Measurement 1		Measurement 2		Difference		<i>P</i>	
	3 months	6 months	3 months	6 months	3 months	6 months	3 months	6 months
Control	84.20±15.51	79.80±18.67	84.00±15.44	79.73±18.54	0.200	0.067	0.189	0.670
Test	81.47±18.77	78.13±17.99	81.40±18.67	77.40±18.58	0.067	0.733	0.334	0.143
Total	82.83±16.97	78.97±18.03	82.70±16.93	78.57±18.28				
<i>P</i>	0.667	0.805	0.682	0.733				

BIC: Bone-implant contact

**Table 8: Palatal/lingual bone-implant contact (%)**

Palatal/ lingual BIC (%)	Measurement 1		Measurement 2		Difference		P	
	3 months	6 months	3 months	6 months	3 months	6 months	3 months	6 months
Control	82.40±12.03	82.40±11.69	82.33±12.09	82.20±10.94	0.067	0.200	0.670	0.677
Test	87.67±12.52	88.13±11.48	87.60±12.22	87.33±11.24	0.067	0.800	0.751	0.171
Total	85.03±12.36	85.27±11.75	84.97±12.24	84.77±11.21				
P	0.250	0.186	0.245	0.215				

BIC: Bone-implant contact

the time the first tooth is extracted. Implant-supported fixed prosthesis has greatly altered the prognosis of oral rehabilitation with an artificial prosthesis. Literature points to several studies that have emphasized on the preservation of bone through the use of various grafts, fillers, and scaffolds.<sup>[4-6]</sup>

When these socket preservation measures are carried out at the time of extraction, it is hypothesized that primary implant stability would be improved due to increased BIC, with all other factors remaining constant. This is best assessed by means of a 3D imaging technique.

The present study was conducted to determine if any significant difference in terms of clinical, radiological, or histological parameters exists, when an extraction socket is grafted with DFDBA and PRF as compared to the ungrafted socket.

The results of this study with respect to the ridge height showed more ridge height loss before extraction on the lingual aspect in the control group ( $8.07 \pm 2.46$ ) as compared to the test group ( $6.40 \pm 1.18$ ) and more ridge height loss before implant placement and 3 months post implant placement on the buccal and lingual aspects in the control group as compared to the test.

Our findings were similar to those reported by Neiva *et al.*<sup>[13]</sup> and in variance to the study conducted by Iasella *et al.*,<sup>[7]</sup> who stated that preserved sites gained height on the buccal aspect. In our study, both groups lost bone height and width, with the control sites losing more than the test sites. In addition, in both the groups, ridge width reduced in a time span of 6–7 months without any significant difference between the groups. Iasella *et al.*<sup>[7]</sup> too found width reduction in both test and control groups with lower loss of ridge width in the test group as compared to the control group. There are innumerable factors that affect ridge width and height dimensions clinically such as age,<sup>[14]</sup> gender,<sup>[14]</sup> compression of the sockets, elevation of flap,<sup>[15]</sup> particle size of the graft material used, and site of extraction.

Another factor that may have an effect on the bone remodeling process after preservation is flap elevation.

However, according to Wood *et al.*,<sup>[15]</sup> the order of magnitude of bone resorption caused by flap reflection alone is about 1 mm because it results in poor blood supply, more bone loss, delayed wound healing, and compromise soft-tissue appearance.

Too small a particle size of the graft material will cause faster resorption and too big will not contribute in socket healing. A study on primates indicated that small-particle bone grafts (100–300  $\mu\text{m}$ ) present a more favorable osteogenic response than large-particle bone grafts (1000–2000  $\mu\text{m}$ ). Our study used a particle size of 500–1000  $\mu\text{m}$ .<sup>[16]</sup> The location of the tooth is not a consideration if the socket has four surrounding walls.<sup>[17]</sup> All our patients, whether in test or control group, had sockets with four surrounding walls.

Froum *et al.*<sup>[17]</sup> opined that the size and the type of the bone defects following tooth extraction often presents similar healing environments with four remaining socket walls and therefore, it does not have an impact which tooth is taken as a comparison as long as the socket has four surrounding walls. All our patients, whether in test or control group, had sockets with four surrounding walls.

Histologically, this study exhibited an increased amount of bone formed in the test group than the control group after a 12–16-week healing period, without any significance. Only 1.5% residual graft particles were seen in the test group, showing significant conversion of this indigenously developed graft material into bone. This was in line with studies by Beck and Mealey<sup>[18]</sup> and Froum *et al.*<sup>[17]</sup> It is our deduction that the DFDBA in conjunction with PRF acted as an osteoconductive material, resulting in greater and faster bone conversion in 12–16 weeks. PRF is a known osteoconductive agent providing growth factors, thereby enhancing the role of graft material.<sup>[8]</sup>

This study on test group and control group showed over 78% BIC, which is higher than 58%–60% of BIC present around successful dental implants according to Lian *et al.*<sup>[19]</sup> According to Naitoh *et al.*,<sup>[12]</sup> the mean rate of BIC on the labial side was 78.3% with grafts and 65.3% without bone grafts. Our study did not substantiate this where BIC was constant irrespective of the use of grafts.

The overall results of this study disprove the null hypothesis that grafted and nongrafted sockets will show no difference in bone loss or BIC with equal conversion to bone. It also proves the alternate hypothesis correct that sockets with grafts will show less bone loss, better BIC, and better conversion to bone as compared to nongrafted sockets.

### Limitations of the study

- The sockets studied were of different regions
- The age of the donor as well as the time lag between death of the donor and harvesting of the material, may determine the amount of Bone Morphogenetic Protein (BMP) that is activated. The same was not considered in this study
- More standardization in terms of each arch being studied separately with a split-mouth design would enhance the findings of this study.

### CONCLUSION

Grafting an extraction socket with an osteoinductive material appears beneficial for the patient in terms of quality and quantity of bone formed and could improve the prognosis of subsequent implantation. Indigenously developed DFDBA material combined with PRF showed promising results as an osteoinductive material.

### Acknowledgment

This research would not have been possible without the valuable support of Department of Oral Pathology, Oxford Dental College under the guidance of Dr. Chaitanya Babu (Professor and Head of the Department) and Dr. Raghavendra, Tutor, Department of Implantology, M S Ramaiah Dental College and Hospital.

### Financial support and sponsorship

Nil.

### Conflicts of interest

There are no conflicts of interest.

### REFERENCES

1. Emami E, de Souza RF, Kabawat M, Feine JS. The impact of edentulism on oral and general health. *Int J Dent* 2013;2013:498305. Doi: 10.1155/2013/498305.
2. Misch CE. *Contemporary Implant Dentistry*. 3<sup>rd</sup> ed. St. Louis: Elsevier;

2013. p. 18.
3. Cosyn J, De Rouck T. Aesthetic outcome of single-tooth implant restorations following early implant placement and guided bone regeneration: Crown and soft tissue dimensions compared with contralateral teeth. *Clin Oral Implants Res* 2009;20:1063-9.
4. Wood RA, Mealey BL. Histologic comparison of healing after tooth extraction with ridge preservation using mineralized versus demineralized freeze-dried bone allograft. *J Periodontol*. 2012;83:329-36.
5. Kresnoadi U, Ariani MD, Djulaeha E, Hendrijantini N. The potential of mangosteen (*Garcinia mangostana*) peel extract, combined with demineralized freeze-dried bovine bone xenograft, to reduce ridge resorption and alveolar bone regeneration in preserving the tooth extraction socket. *J Indian Prosthodont Soc* 2017;17:282-8.
6. Jayaraman S. Intervention for replacing missing teeth: Alveolar ridge preservation techniques for dental implant site development - evidence summary of Cochrane review. *J Indian Prosthodont Soc* 2015;15:381-5.
7. Iasella JM, Greenwell H, Miller RL, Hill M, Drisko C, Bohra AA, *et al.* Ridge preservation with freeze-dried bone allograft and a collagen membrane compared to extraction alone for implant site development: A clinical and histologic study in humans. *J Periodontol* 2003;74:990-9.
8. Ehrenfest DM, Del CM, Diss A, Mouhyi J, Charrier J. Three-dimensional Architecture and Cell Composition of a Choukroun's Platelet-Rich Fibrin Clot and Membrane. *J periodontol* 2010;81:546-55.
9. Kim DM, De Angelis N, Camelo M, Nevins ML, Schupbach P, Nevins M. Ridge preservation with and without primary wound closure: A case series. *Int J Periodontics Restorative Dent* 2013;33:71-8.
10. Iwaniec UT, Wronski TJ, Turner RT. Histological analysis of bone. *Methods Mol Biol* 2008;447:325-41.
11. Misch CE. *Contemporary Implant Dentistry*. 3<sup>rd</sup> ed. St. Louis: Elsevier; 2013. p. 39-50.
12. Naitoh M, Nabeshima H, Hayashi H, Nakayama T, Kurita K, Ariji E. Postoperative assessment of incisor dental implants using cone-beam computed tomography. *J Oral Implantol* 2010;36:377-84.
13. Neiva RF, Tsao YP, Eber R, Shotwell J, Billy E, Wang HL. Effects of a putty-form hydroxyapatite matrix combined with the synthetic cell-binding peptide P-15 on alveolar ridge preservation. *J Periodontol* 2008;79:291-9.
14. Engeland CG, Bosch JA, Cacioppo JT, Marucha PT. Mucosal wound healing: The roles of age and sex. *Arch Surg* 2006;141:1193-7.
15. Wood DL, Hoag PM, Donnenfeld OW, Rosenfeld LD. Alveolar crest reduction following full and partial thickness flaps. *J Periodontol* 1972;43:141-4.
16. Geurs N, Ntounis A, Vassilopoulos P, Van der Velden U, Loos BG, Reddy M. Using growth factors in human extraction sockets: A histologic and histomorphometric evaluation of short-term healing. *Int J Oral Maxillofac Implants* 2014;29:485-96.
17. Froum S, Cho SF, Rosenberg E, Rohrer M, Tarnow D. Extraction sockets implanted with bioactive glass or demineralized freeze. *J Periodontol* 2002;73:94-102.
18. Beck TM, Mealey BL. Histologic analysis of healing after tooth extraction with ridge preservation using mineralized human bone allograft. *J Periodontol* 2010;81:1765-72.
19. Lian Z, Guan H, Ivanovski S, Loo YC, Johnson NW, Zhang H. Effect of bone to implant contact percentage on bone remodelling surrounding a dental implant. *Int J Oral Maxillofac Surg* 2010;39:690-8.